

## Assessment of Lateral Patella Dislocation Corrections and Evaluation of Current Concepts Perceptive Bangladesh

Sofikul Islam<sup>1\*</sup>, Munzur Rahman<sup>1</sup>, Ataul Haque<sup>2</sup>, Mohammad Rajib Mahmud<sup>3</sup>, Asadujjaman Azad<sup>4</sup>, Mahfuzzaman<sup>5</sup>, Abu Zahid Ph. D<sup>6</sup>

<sup>1</sup>Assistant Professor, Department of Orthopaedic Surgery, Rajshahi Medical College Rajshahi, Bangladesh


<sup>2</sup>Medical Officer, Department of Orthopaedic Surgery, Joypurhat 250 bed District Hospital, Joypurhat Shador, Rajshahi, Bangladesh

<sup>3</sup>Jr Consultant, Department of Orthopaedic Surgery, 250 Bedded Bongamata Sheikh Fazilatunnesa Mujib General Hospital, Sirajganj, Bangladesh

<sup>4</sup>Medical Officer, Department of Orthopaedic Surgery, Divisional Police Hospital, Rajshahi, Bangladesh

<sup>5</sup>Jr Consultant, BIHS General Hospital, Dhaka, Bangladesh

<sup>6</sup>Associate Professor, Department of Anesthesiology, Rajshahi Medical College, Bangladesh

Original Research Article	DOI: 10.62469/tmb.v01i01.004
<p><b>*Corresponding Author:</b> Sofikul Islam</p> <p><b>Citation:</b> Sofikul Islam <i>et al.</i> (2023); Assessment of Lateral Patella Dislocation Corrections and Evaluation of Current Concepts Perceptive Bangladesh. <i>iraetc med. bull.</i> 1(1) 17-23.</p> <p></p> <p>This work is licensed under a Creative Commons Attribution- NonCommercial 4.0 International license.</p>	<p><b>Abstract: Background:</b> Many different methods have been proposed to treat recurrent satellite dislocation in adolescents, one of the most famous being Galeazzi's semitendinosus tenodesis, modified by Baker. This study aimed to assess the mid-term results of this technique and assess if the preoperative type of the patellofemoral connection influences the results and restore. The efficacy of patellofemoral congruency using static patellofemoral congruency and dynamic computational tomography (CT). <b>Materials and Methods:</b> Multicentered based, non-randomized quasiexperimental prospective study was performed in Rajshahi Medical College Hospital, Rajshahi, Bangladesh, from January 2020 to December 2022. The research consisted of 14 patients with an average 11.6-year age Tanner stage B3 (16 knees), with at least 2-3 occurrences of patellar dislocation. The patients had surgery utilizing the Galeazzi method. Total 14 patients and static and dynamic CT were pre-operatively evaluated for at least 4 years. The clinical monitoring was carried out following Crosby and Insall criteria. <b>Results:</b> Clinical follow-up results were excellent at 62.5% and good at 37.5%. A high patella has been detected in 7 out of 16 knees in two groups: A, high Patella; B, not high Patella. The results collected with static CT indicate that all knees of the Patella are satisfactorily compatible. Data from dynamic CT revealed varied outcomes between group A and group B. With a quadriceps contraction, a high preoperative patella stays high and exhibits the tilt and subluxation shift again. In group B, the data acquired from dynamic CT is similar to the data obtained from static CT. <b>Conclusions:</b> This method provides excellent clinical outcomes in the mid-term. However, the dynamic CT indicated that semitendinosus tenodesis alone is insufficient to stabilize the Patella in those individuals with high Patella.</p> <p><b>Key Words:</b> Trochlear dysplasia, Lateral patella dislocation, Medial patellofemoral ligament.</p>
<p>  IRAETC Publisher  <b>Publication History-</b> Received: 14.01.2023  Revised: 01.02.2023  Accepted: 09.02.2023  Published: 12.02.2023  </p>	

## INDICATIONS

The word "patellar instability" is defined in many ways. For instance, it indicates a clinical entity or diagnostic. It is utilized as a physical test indication indicating the capacity to translate the Patella out of the groove Passively. <sup>1</sup> It could be a Symptom, usually an exit from the knee due to the slide of the patella Inhibition of the painful consequence of trochlear groove or quadriceps. The Patellofemoral joint semanticity, its symptoms, traumas and illnesses are Especially perplexing. The need to develop uniform nomenclature Communication between clinicians and improved scientific utility There is a discussion of patellofemoral studies. <sup>2</sup> The word patellar dislocation is employed for this text to represent a clinical entity when a traumatic event usually interrupts or earlier—Patella's undamaged containment inside the femoral groove. When checking the historical patellar instability debates, however, must be held by the reader. Mind the terminology misunderstanding to date. Conditions such as dislocation, instability, Malalignment and aberrant tracking are often employed without Accurate definitions without explicit severity criteria. Often this is the case for Terms that define surgical indications. To the degree that language is used, It is obvious that the knowledge of the knee extender function and its harm Limited knowledge of the patellofemoral disease processes and injury.

## MATERIALS AND METHODS

From January 2020 to December 2022., 14 individuals (4 male and 10 female patients; mean age 11.1 years, range 9.2–13.1; 16 knees, 2 female patients with bilateral dislocation) who fulfilled the following criteria were studied.

1. Recurrent patellar dislocations (at least 2–3 episodes);
2. Tanner stage B3;
3. Signs of subluxated and tilted Patella assessed by CT

4. Static and dynamic CT clinical and instrumental assessment after at least 2 years of following;
5. No associated meniscal or cartilaginous injuries.

All patients and their parents had written permission and accepted inclusion in this research before the surgical procedure. All patients were pre-operatively assessed with knee Q-angle measurement and ligamentous laxness evaluation. The follow-up clinical assessment was conducted based on the Crosby and Insall criteria (1976) [Table 1].

**Table 1: Crosby and Insall's criteria (1976).**

<i>Grade</i>	<i>Descriptions</i>
<i>Excellent</i>	No pain, normal exercise, all sports, full-range, normal knee subjectively
<i>Good</i>	Occasional discomfort, steepness or instability, little impact sports participation, minimal bending loss, the knee of the patient better or normal
<i>Fair to poor</i>	Pain mostly altered symptoms but included repeated subluxation or significant bending loss, further treatment required in certain instances

### Statistical methods

Combined t-tests have been used to assess pre- and after-operative data where parametrical and Pearson correlation were present. Postoperative data comparison has been used. The results for each group are provided as an average and standard difference, an average difference between groups and an interval of 95 percent trust is supplied. A  $p < 0.05$  value was deemed significant. The Statistical analysis has been performed using the computer software GraphPad prism 5.

## EVALUATION AND ASSESSMENT

### Physical examination

It is essential constantly to determine if discomfort or instability affects the patellofemoral articulation. Acute dislocations in patellar knees occur with modest knee bending at a rotary external rotation moment or sometimes directly affecting the medial Patella. This corresponds to when the Patella is biomechanically most susceptible due to lack of congruence in the early flexion since the Patella does not yet have a bony restriction on the trochlea. The Q-angle is significantly elevated by increased tibial external rotation during quadriceps exercise. Serious, genuine valgum may further enhance patellar instability risk since the Q angle with activation of the quadriceps, and the lateral patella vector are increased. As the knee bends, the Patella is caught on the side knee to make dislocation complete. The pain-related buckle, frequently mistaken by patients as patella instability, is an abrupt inhibition of the quadriceps by painful stimuli, such as the loading of the hopper during escalation or descent. A history of what happened when the knee was already flexible, such as on the stairs, is an indication of the genesis of the hump linked to pain rather than instability.

### Diagnostic imaging

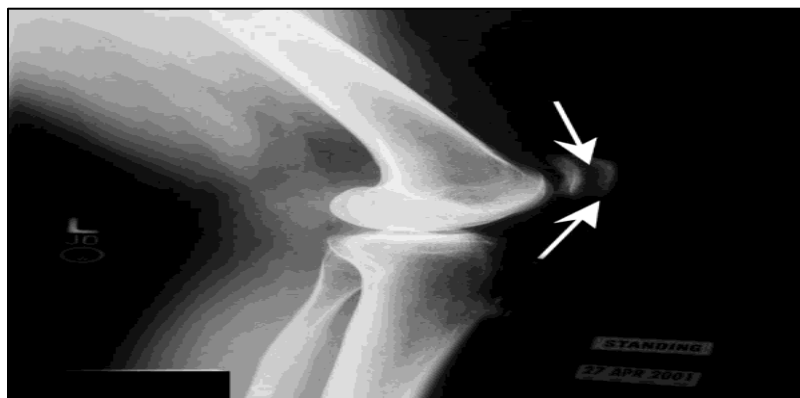A typical 3-view radiography series comprises a posteroanterior, side and 45° axial flexion Merchant knee view. The axial vistas of the Patella are never useful with deeper flexion and may actually be deceptive because the Patella is usually centrally located in the trochlea. A true lateral knee radiograph may provide an insight into the existence of trochlear dysplasia and Patella Alta. The Caton–Deschamps Index (CDI), although many measures are available to quantify the patellar height, is probably best assessed in the case of Patella Alta, given the requirement for a lateral radiographer at 30° flexion [Figure 1]. The measurement contrasts with the Blackburn–Peal Ratio, which requires lateral radiographs to be acquired at a knee flexion of 30°, and in addition, the CDI does not include a nonarticulated patella nose as an Install–Salvati ratio in the calculation.<sup>3</sup> To calculate the angle, patellar, and congruence angles, we recommend an axial slope view with the knee in 30° bend. The Laurine image, acquired at a knee flexion of 20° and the beam from caudal up to cephalad, is an extra valuable axial radiograph. These two axial radiograms are a reliable method to acquire information on early flexion patellar subluxation due to increasing flexion angles with Patellary reengagement from other axial patellar visions. But these x-rays cannot properly see the proximal trochlea and overlook the existence of a supratrochlear spur, which is best recognized on the secondary x-ray. Further comprehensive tests of trochlear dysplasia, patellar height and TT lateralization have been better evaluated by sophisticated diagnostic imaging, notwithstanding what may be gleaned from the basic X-rays [Figure 1].

### Factors of etiology and risk:

Historically, patellar dislocations and subluxations were primarily considered feminine dislocations.<sup>4</sup> Although few research studies are population-based and few are current (most studies come from surgical studies), literature

reviews on active patellar dislocations show an evident preponderance of male people. The equal impact has been shown in population-based studies. Some studies have shown recurrent patellar dislocations in women more frequently.<sup>5</sup> These results may indicate a sampling defect except for a population-based study. The proportional risk of patellar dislocation among men and women cannot be identified based on this study.

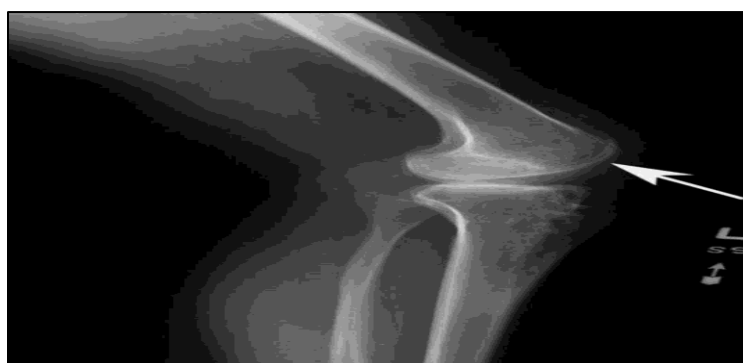Patella Alta (Fig. 1) is the most consistent physical examination characteristic linked with patellar instability.<sup>6</sup> At least one school of thinking identifies patella Alta as a type of dysplasia by quadriceps shown by shortening the quadriceps muscular tendon complex.<sup>7</sup> Regardless of the cause of Patella Alta, her relationship indicates that it plays an essential role in the likelihood of initial dislocation, subsequent redislocation or both. To the degree that a high-ranking patella bends the trochlea later than that which is usually set?



**Figure 1: This lateral knee x-ray shows a high patella. The ratio of the slurry to the slurry tendon (P: PT) should be  $1 \pm 0.2$ .**

It is simple to understand how patella alta may raise the passive patellar movement (laxity) limit by decreasing the joint restriction supplied by the trochlea for a certain angle of bending and sulcus. Torsional defects in patellofemoral instability are observed, including increased external tibial torsion and torsional femoral deformations.<sup>8</sup> Others think that external tibial torsion has much too much variance among the people to be of great therapeutic use and do not distinguish between patellar dislocators and controls in measures of tibial torsion. The quadriceps angle or Q corner physical test measurement is higher in individuals with a history of patellar subluxation. This is true of the wounded knee and the reverse knee. Other investigations have shown no higher Q angles than controls in a patellar subluxation group of patients. In patient with patellar instability, lateral tubercle displacement is more objectively assessed by axial computed tomography (CT) images.<sup>7</sup>

Trochlear dysplasia, generally characterized by the flattening of the femoral sulcus angle, has been identified as a patellar stability factor since 1915 in an Albee surgical report that dealt with the correction of trochlear dysplasia with superolateral tracheoplasty treatment.<sup>9</sup> Initially described the practicality of the actual lateral knee x-ray to investigate the trochlea and its dysplasias. Dejour *et al.*<sup>7</sup> have recently examined determinants of x-ray patellar instability and identified the most consistent x-ray sign in patients with objective patellar instability as opposed to testing for trochlea dysplasia (Fig. 2).

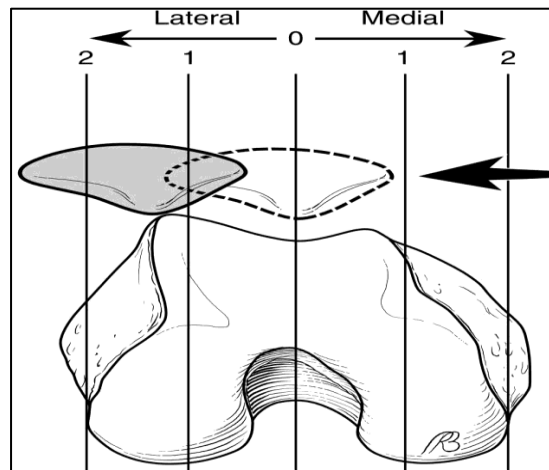


**Figure 2: This side knee x-ray shows dysplasia type I; the crossing of two condylar contours with the trochlear floor contour is symmetrical and proximal. Note that a maquette operation and patellectomy were done in this patient with patella instability.**

Soft tissue dysplasia is often observed in patellar dislocators. Patellar instability is linked with muscular weakness or imbalance. Whether it was developmental or the outcome of repeated dislocations is unknown. Ligamentous hyperlexia is also characterized as an increased mechanism of passive movement of ligamentous restrictions of the patellar in patients with patellar instability. In a more recent population investigation, there were no links between widespread hyperlexias and the main patellar dis-location.<sup>10</sup>

#### **Patellar stability:**

The two components of the knee extension process primarily affect dial and side patellar shifts: restraints and ligamentous tethers. These variables work together to establish passive satellite displacement limitations.

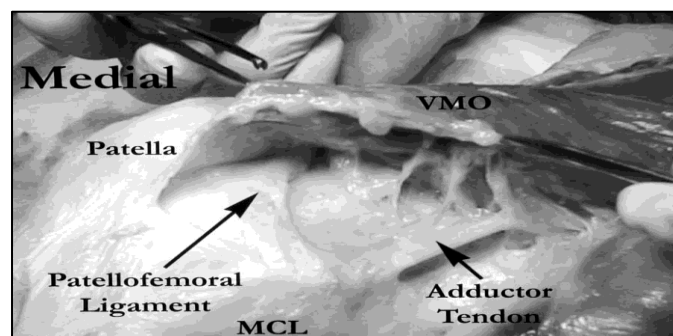


**Figure 3: The kneecap's rest posture, with the knee extending, is regarded to be "zero." Manual force is used to quantify medial or lateral translation by "quadrant" (one-quarter the width of the Patella). This image shows two quadrants of lateral patella translation.**

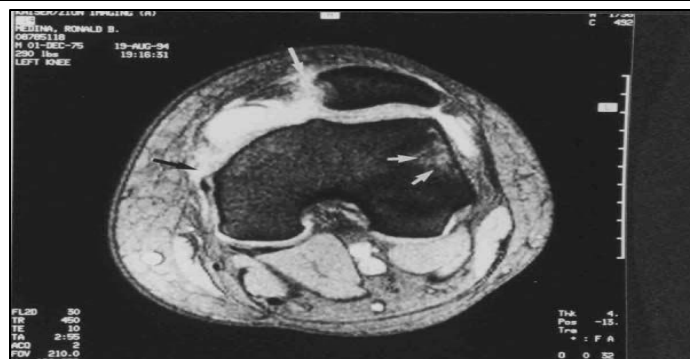The distinction between common and pathological joint motion limitations must be determined to comprehend the role of anyone anatomical element in patellar instability after patellar dislocations. For patellar instability, this means that the boundaries of patella displacement from its position in the trochlear groove may be measured. Kolowich *et al.*<sup>11</sup> split the slipper into four quadrants, slippers and passive slippers, medial or lateral physical exam displacement as a qualitative indication of laxity and tightness of slippery limits. The authors claimed that medial or lateral baseline movement exceeded two quadrants (laxation).

#### **Anatomy of the medial soft tissue stabilizers of the Patella:**

MCL on the medial epicondyle (Fig. 4). This is where it has a firm bony attachment. Some superficial fibres of the MPFL can be seen to cross over the passive stabilizers are present as homogeneous joint motion restrainers. The patellar ligament or patellar retinacular complexes are identified in the patellar femoral joint and comprise patellofemoral and patellotibial ligaments. More recently, patellomeniscal ligaments have been discovered in the literature. The description and appointment of passive stabilizers in English-language literature are inconsistent. These are briefly reviewed. Warren and Marshall published a paper in 1979 with a comprehensive description of the medial knee side based on the dissection of 154 newly frozen cadavers. The MPFL and the superficial medial collateral ligament (MCL) were believed to form part of layer 2, which is an extracapsular structure.



**Figure 4: The medial patellofemoral ligament is distal to the vistas medialis obliques (VMO) muscle and courses from the medial patella border to insert on the medial epicondyle.**



**Figure 5: Axial gradient-echo imaging (TR/TE, 450/10, flip angle 30°) showing two distinct retinacular injuries (big white and black arrow) and lateral femoral condyle bruising (small white arrows).**

#### **Clinical significance of medial patellofemoral ligament:**

Much research shows that MPFL has clinical significance in patellofemoral stability. According to Conlan *et al.* cadaveric cutting tests, the MPFL provides an average of 53% of the reinforcing force against lateral patellar displacement. According to Desio *et al.*,<sup>9</sup> MPFL contributes 60% of total restraining force against lateral patellar movement (range 41–80%). Hautamaa *et al.* discovered that when the MPFL was decreased, lateral patellar dislocation increased by 50%. Hautamaa *et al.* also showed that MPFL restoration restored normal lateral displacement levels.<sup>12</sup> Additional Repairation of the other retinal components does not offer any additional stability. These biomechanical Studies indicate the MPFL be repaired or restored to reinstate normal passive limits Against lateral movement of the patellar.

#### **Nonoperative Management**

Studies indicate the beneficial influence of VMO restructuring. In many cases, first patella dislocation events are conservatively administered, enabling effusion to be resolved, retrofitting the VMO and allowing an acceptable restoration of mobility and functions without recurrence. Patellar tape and stabilizing braces were also utilized to minimize the patients' subjective sense of patellar instability. For many, nonoperative treatments does not lead to a repeated subjective patellar anxiety, which is often suggestive of residential micro instability without frankly dislocated subluxations. In these cases of unsuccessful conservative treatment, the above-mentioned additional work is needed with diagnostic imaging and consideration of surgical options.

#### **Operative Management**

If sufficient history and physical examination have been achieved, diagnostic imagery has been acquired, and an operating technique has been identified, many possible operational methods exist to help address the underlying pathology. While reconstruction of the MPFL, tracheoplasty and TTO is the most common method for combating Patellar instability, it is important to remember that distal femoral osteotomy and denotational osteotomy can be indicated and effective when setting severe morphological variances of genuine valgus or femoral anteversion. In the skeletally immature patient, Hemi epiphysiodesis decreased patellar instability in the context of severe genu valgus.<sup>13</sup> Combined distal femoral opening wedge osteotomy operations with authentic valgus were able to improve overall coronary limb alignment and objective results measures and prevent future spatula displacement. Combined supracondylar distal femoral delocalization osteotomies and MPFL reconstructions in patients with a >25° femoral anteversion and recurring patellar dislocations have encouraged short-term statistically significant improvements in the International Knee Documentation Committee (IKDC) outcomes and visual analogue scale without further pattern dislocation.

## **RESULTS**

14 patients met the inclusion criteria and had an average 2-year follow-up (Range 1.8–2.0). According to the criteria of Crosby and insall, 62.5% of knees exhibited outstanding results, 37.5% had good results, and no instances had bad or worse results (Table 2). The only problem described was a passing saphenous nerve. Since preoperative assessment revealed a high patella (PH C2 mm) in 7 out of 16 knees, two subgroups of patients were considered: those with the high Patella (subgroup A) and the non-subgroup B before surgery. The kind of patellofemoral Malalignment was defined by sub-luxated and inclined Patella, which were more evident by dynamic CT in all knees; the Parameters utilized for this assessment include PTA and FPD. The mean TAGT value was 21.5 mm (18-25 range) and did not change after the procedure.



PTA evaluation has shown a statistically significant difference between static and dynamic CT preoperative ( $p=0.01$ ) values but not a follow-up differential ( $p=0.25$ ). Statistically relevant There was a difference ( $p=0.0001$ ) between static PTA and static PTA in preoperative monitoring and dynamic PTA in preoperative ( $p=0.0001$ ). The  $p$ -value in subgroup A was also significant for the dynamic PTA monitoring of static PTA ( $p = 0.003$ ). In subgroup B, it is essential to note. It There was no statistically significant difference between static PTA and dynamic PTA either pre-op ( $p=0.072$ ) or afterwards ( $p=0.169$ ). In all cases, evaluation of the FPD showed statistically significant changes between the CT's static and dynamic preoperative values ( $p\backslash0.0001$ ) but not ( $p=0.096$ ). In preoperative evaluation, subgroup A ( $p = 0.0002$ ) was significantly more meaningful than subgroup B ( $p = 0.013$ ).

Table 2: Results of 16 knees:

Grade	Knees	%
Excellent	10	62.5
Good	6	37.5
Fair to poor	0	0

## DISCUSSION

At least 4 years of follow-up, clinical evidence confirms that Galeazzi semitendinosus tenodesis may provide excellent mid-term clinical outcomes in skeletally immature individuals with recurrent Patella dislocation with a sufficient lateral release and medial retinacular reepling modified by Baker.<sup>14</sup> Analysis of the data obtained with the static CT revealed that the Patella achieved a good concord with trochlea subluxate and inclined before surgery in all knees. The PTA, Patellar Inclination Index, was normal in every instance, as was the case with the FPD, patellar subluxation index. PH was also normalized in individuals with pre-operatively elevated patellas. Data analysis using dynamic CT revealed a difference in outcomes between Subgroup A and Subgroup B. In preoperative high patella subgroup A, the Patella was high. However, the changes in PTA and FPD revealed lower values than in preoperative data. Quadriceps contraction. The results obtained with dynamic CT in Subgroup B (not high Patella) are similar to those collected with static CT. The modified method of Galeazzi thus normalized the elevated Patella in static CT, but the correction has not been preserved in the dynamic evaluation.

The research showed that the semitendinosus septum could not alone counterbalance the force of the quadriceps when reconstructing MPFL in individuals with high preoperative patellae. The preservation of the aberrant patellofemoral connection was never considered related to a fresh dislocation at least two years following surgery. The research enables us to maintain that a high patella preoperative influences the instrumental (CT) result of this operational method employed in the recurrence of the Patella in teenagers. During the 1990s, many anatomical and biomechanical investigations underlined the main function of the MPFL as a restriction among the medial static cellular stabilizers. Conlan<sup>15</sup> said, "MPFL has 53 percent of the overall medial retention force." Hautamaa and Desio said, "MPFL provides an average of 50 percent of the total retention force and 60 percent of the total retention force". The percentage contribution of MPFL lateral dislocation resistance has been determined to be 13%.<sup>13</sup> Our emphasis on MTL rebuilding nonetheless emphasizes its function in resisting the pulling power of the quadriceps muscle and not the lateral patella dislocation, as was abundantly emphasized in many investigations. The rebuilding of the MPFL alone may be seen in the absence of predisposing circumstances.

## CONCLUSION

This research demonstrates the ability to address the functional issue of satellite dislocation by semitendinosus tenodesis and achieves acceptable pathogenic congruence in all knees, as shown by static CT. Dynamic CT has nevertheless shown that this method cannot prevent upward displacement of the Patella in individuals with high patellae by pre-operatively preventing subluxation and tilting of the Patella. On the CT evaluation with quadriceps contraction, the restriction of this procedure was observed. Maintaining this Malalignment under dynamic circumstances may pose a danger of chondromalacia. These findings have brought advances to this procedure by increasing the resistance to semitendinosus or by having more anchor points in the Patella, particularly in knees pre-operatively with a high patroller.

## REFERENCES

1. Hawkins RJ, Bell RH, Anisette G. Acute patellar dislocations. The natural history. *Am J Sports Med.* 1986;14(2):117-120. doi:10.1177/036354658601400204
2. Stanitski CL. Management of patellar instability. *J Pediatr Orthop.* 1995;15(3):279-280. doi:10.1097/01241398-199505000-00001
3. Brown GD, Ahmad CS. Combined medial patellofemoral ligament and medial patellotibial ligament reconstruction in skeletally immature patients. *J Knee Surg.* 2008;21(4):328-332. doi:10.1055/s-0030-1247840

4. Aglietti P, Insall JN, Cerulli G. Patellar pain and incongruence. I: Measurements of incongruence. *Clin Orthop*. 1983;(176):217-224.
5. Buchner M, Baudendistel B, Sabo D, Schmitt H. Acute traumatic primary patellar dislocation: long-term results comparing conservative and surgical treatment. *Clin J Sport Med Off J Can Acad Sport Med*. 2005;15(2):62-66. doi:10.1097/01.jsm.0000157315.10756.14
6. Urch SE, Tritle BA, Shelbourne KD, Gray T. Axial linear patellar displacement: a new measurement of patellofemoral congruence. *Am J Sports Med*. 2009;37(5):970-973. doi:10.1177/0363546508328596
7. Arendt EA. MPFL reconstruction for PF instability. The soft (tissue) approach. *Orthop Traumatol Surg Res OTSR*. 2009;95(8 Suppl 1):S97-100. doi:10.1016/j.otsr.2009.09.002
8. Fulkerson JP, Schutzer SF, Ramsby GR, Bernstein RA. Computerized tomography of the patellofemoral joint before and after lateral release or realignment. *Arthrosc J Arthrosc Relat Surg Off Publ Arthrosc Assoc N Am Int Arthrosc Assoc*. 1987;3(1):19-24. doi:10.1016/s0749-8063(87)80005-1
9. Desio SM, Burks RT, Bachus KN. Soft tissue restraints to lateral patellar translation in the human knee. *Am J Sports Med*. 1998;26(1):59-65. doi:10.1177/03635465980260012701
10. Urch SE, Tritle BA, Donald Shelbourne K, Gray T. Axial Linear Patellar Displacement: A New Measurement of Patellofemoral Congruence. *Am J Sports Med*. 2009;37(5):970-973. doi:10.1177/0363546508328596
11. Drez D, Edwards TB, Williams CS. Results of medial patellofemoral ligament reconstruction in the treatment of patellar dislocation. *Arthrosc J Arthrosc Relat Surg Off Publ Arthrosc Assoc N Am Int Arthrosc Assoc*. 2001;17(3):298-306. doi:10.1053/jars.2001.21490
12. Hautamaa PV, Fithian DC, Kaufman KR, Daniel DM, Pohlmeier AM. Medial soft tissue restraints in lateral patellar instability and repair. *Clin Orthop*. 1998;(349):174-182. doi:10.1097/00003086-199804000-00021
13. Panagiotopoulos E, Strzelczyk P, Herrmann M, Scuderi G. Cadaveric study on static medial patellar stabilizers: the dynamizing role of the vastus medialis obliquus on medial patellofemoral ligament. *Knee Surg Sports Traumatol Arthrosc Off J ESSKA*. 2006;14(1):7-12. doi:10.1007/s00167-005-0631-z
14. Aulisa AG, Falciglia F, Giordano M, Savignoni P, Guzzanti V. Galeazzi's modified technique for recurrent patella dislocation in skeletally immature patients. *J Orthop Sci Off J Jpn Orthop Assoc*. 2012;17(2):148-155. doi:10.1007/s00776-011-0189-1
15. Conlan T, Garth WP, Lemons JE. Evaluation of the medial soft-tissue restraints of the extensor mechanism of the knee. *J Bone Joint Surg Am*. 1993;75(5):682-693. doi:10.2106/00004623-199305000-00007